Pegem Journal of Education and Instruction, Vol. 14, No. 3, 2024 (pp. 1381-1394)

RESEARCH ARTICLE WWW.PEGEGOG.NET

# Femoral Deformity, Shortening Osteotomy, and Neurovascular Safety in Complex Dysplastic Hip Reconstruction

**Islam Mohamed Ibrahim Mohamed[1], Khaled Edris Abdelrahman[2], El-Sayed El-Etewy Soudy[2], Ehab Mohamed Shehata[3]**

[1]Assistant Lecturer of Orthopedic Surgery; [2]Professor of Orthopedic Surgery; [3]Assistant Professor of Orthopedic Surgery, Faculty of Medicine, Zagazig University, Zagazig, Egypt.

Corresponding author: Islam Mohamed Ibrahim Mohamed

## ABSTRACT

Femoral reconstruction in severe developmental dysplasia of the hip is complicated by narrow canals, excessive anteversion, abnormal offset, contracture and longstanding proximal displacement. This narrative review examines femoral component planning, approach selection, subtrochanteric shortening osteotomy, soft-tissue balancing and prevention of neurological and mechanical complications during arthroplasty for high-riding dysplastic hips. The choice of stem and osteotomy must be coordinated with the position of the reconstructed acetabular center, because the desired reduction distance determines nerve tension and may alter fixation requirements. Transverse and more complex osteotomy geometries offer different mechanical advantages without a universally established superior option. Reports of considerable symptomatic improvement should be interpreted alongside the risks of intraoperative fracture, osteotomy nonunion, dislocation and nerve palsy. Existing investigations are commonly observational and vary in anatomy, implant design, operative technique and complication definitions. A staged operative approach that identifies the mechanism of difficult reduction, corrects torsion, protects neural structures and verifies stable femoral fixation offers a coherent strategy for complex cases. Rehabilitation requires individualization according to osteotomy and implant stability, while long-term follow-up must include union, component fixation and gait recovery. Better prospective reporting of femoral morphology, length correction and neurological outcomes is needed to strengthen technique selection.

Keywords: Developmental dysplasia of the hip, Femoral shortening, Subtrochanteric osteotomy, Nerve palsy, Hip reconstruction

## INTRODUCTION

Severe developmental dysplasia combines altered proximal femoral anatomy with chronic displacement, torsional abnormality and contracted periarticular tissues. Arthroplasty therefore entails more than replacing the joint surfaces: femoral rotation, length, fixation and neurological safety must be planned together with the reconstructed acetabular center. A standardized stem or fixed shortening threshold cannot accommodate the full spectrum of deformity. This review considers the femoral and soft-tissue challenges that are most consequential in high-riding dysplastic hips, while emphasizing reconstructive mechanisms and prevention of adverse events. [1]

Research gap and aim. Evidence on shortening osteotomy and stem selection consists largely of observational series with variable anatomical grades and complication definitions. The aim is to synthesize the pre-2025 literature into an integrated framework for choosing femoral reconstruction, controlling lengthening, protecting nerves and managing postoperative recovery. Additional uncertainty surrounds the relationship between measured limb lengthening, the degree of soft-tissue tension, osteotomy design, and the timing of neurological

recovery. The review therefore separates observed complications from hypotheses about their causes and prioritizes actionable anatomical reasoning.

## Femoral morphology in severe dysplasia

Severe developmental dysplasia affects the femur as profoundly as the acetabulum. The proximal femur may be narrow, excessively anteverted, valgus or rotationally distorted, with a small head and abnormal trochanteric relationship. These changes are not adequately described by the height of dislocation alone. A reconstruction that restores the cup to the true acetabulum can fail to produce a stable or functional hip if the femoral version, offset and soft-tissue constraints are ignored. The technical sequence should begin with an anatomical description of the canal and the proximal femoral segment rather than an assumption that a standard primary stem will fit. [2]

The femoral canal in a high-riding dysplastic hip can be both small and unusually shaped along its length. The metaphysis may offer limited rotational control, while the diaphyseal axis may not align with the proximal anatomy. A stem that fills the distal canal can produce an unsatisfactory proximal orientation, and forcing a standard geometry can create a fissure or fracture. The available bone stock, canal isthmus and previous childhood operations should therefore be assessed before choosing a stem. Small stature alone does not predict canal shape, making individualized imaging and templating essential. [3]

Excessive native femoral anteversion is an important determinant of combined component orientation. Simply reproducing this torsion with an anatomically designed or metaphyseal-fitting stem may increase the risk of anterior instability or limit the range of motion. Correcting it requires careful consideration of the fixation segment and available implant geometry. A modular stem or a corrective osteotomy may offer independent control of rotation, but each adds interfaces or healing demands. The objective is not a uniform postoperative version number; it is an orientation that harmonizes with cup position, impingement clearance and residual soft-tissue tension. [4]

The greater trochanter and abductors may be displaced relative to the reconstructed center of rotation. Long-standing shortening and altered muscle direction can lead to weakness and persistent limp despite pain relief. The femoral plan must therefore specify intended offset, trochanteric height and achievable length correction. Overlengthening to obtain an impressive radiograph may compromise nerve safety, while inadequate offset can weaken abduction and destabilize the joint. Patient-specific restoration is better judged by balanced tension and functional mechanics than by absolute symmetry with an opposite hip that may also be dysplastic. [5]

## Preoperative assessment and risk stratification

Assessment begins with the clinical history of childhood treatment, previous pelvic or femoral osteotomy, gait disturbance, perceived shortening and neurologic symptoms. Prior surgery may leave retained hardware, cortical scars, deformity and adhesions that alter both the approach and the ability to pass a stem. Examination should document hip flexion contracture, rotational range, abductor function, knee alignment and spinal compensation. These details explain why the same radiographic displacement can create very different reduction difficulties. An operative plan limited to the hip radiograph risks overlooking constraints that are outside the acetabulum. [6]

Leg-length discrepancy should be divided into true skeletal inequality, apparent difference from pelvic obliquity and functional adaptation at the spine or knee. Block testing can help describe standing balance, while full-length imaging may be useful when the apparent discrepancy is large or complex. In bilateral dislocation, there may be no normal side for comparison. Preoperative discussion should avoid a guarantee of equal postoperative limb lengths and instead describe the relationship between planned correction, nerve tension and the potential need for osteotomy. Patient satisfaction is influenced by whether these limitations are explained before surgery. [7]

Radiographs should provide an estimate of the femoral canal diameter, proximal morphology and expected seating level of trial stems. CT can clarify extreme torsion, previous osteotomy planes and the relationship

between the proximal and distal axes. The surgeon should anticipate whether a distal fixation stem is needed and whether such fixation may conflict with a planned shortening osteotomy. A detailed implant inventory is particularly important in severe dysplasia because intraoperative changes in stem length, geometry or modularity may be necessary. Planning should include the possibility of fracture fixation and alternative reconstruction methods. [8]

Risk assessment should incorporate conditions that modify bone healing and perioperative complications, including nutritional status, osteoporosis, smoking, diabetes and prior infection, alongside the expected lengthening and osteotomy complexity. These factors are not unique to dysplasia, yet their consequences may be magnified when the procedure includes a subtrochanteric cut and prolonged operative exposure. The patient should understand the distinction between commonly expected rehabilitation difficulties and uncommon but consequential events such as nerve palsy, dislocation, nonunion and femoral fracture. Consent becomes more useful when probabilities are framed in relation to procedural complexity rather than generic arthroplasty risk alone. [9]

## Approach selection and surgical exposure

Posterior, direct lateral and anterior approaches have all been used for arthroplasty in dysplastic hips. Selection should reflect the surgeon's experience, the required access to the true acetabulum, the need for femoral osteotomy and the condition of the abductors. A familiar approach performed with controlled exposure may be safer than an unfamiliar one chosen for a theoretical advantage. Severe high dislocation often demands substantial soft-tissue work and a wider view of the femur than uncomplicated primary arthroplasty. Technical comparisons should therefore account for deformity severity instead of attributing all outcomes to the skin incision or interval. [10]

The posterior approach can provide extensive access for femoral preparation and osteotomy but requires meticulous attention to posterior stability. A lateral approach may improve exposure of the abductors and acetabulum, yet direct muscle handling can contribute to postoperative weakness or limp. Anterior approaches may offer a muscle-sparing interval in selected cases, but femoral access and management of extensive deformity can be technically demanding. The important comparison is whether the approach permits accurate reconstruction and secure fixation without avoidable tissue injury. Reported approach-related differences often reflect surgeon selection and learning curves. [11]

Abnormal landmarks create a risk of incorrect dissection planes and injury to nearby neurovascular structures. Prior dislocation stretches and relocates the capsule and muscles, and a high false socket can obscure the true acetabulum. Careful identification of osseous landmarks before deep release reduces the risk of misdirected reaming or excessive traction. Circumferential releases should be staged and their effect on reduction reassessed rather than undertaken indiscriminately. Controlled exposure is especially important when a femoral shortening osteotomy is anticipated, because unplanned forceful reduction may create both neurologic strain and mechanical complications. [12]

The approach must accommodate the complete operation, not only cup placement. Surgeons should ask whether they can deliver the femur safely, identify an osteotomy level, control rotational alignment and stabilize a fracture should one occur. Extensile exposure or additional fixation may be necessary in previously operated hips. This should be anticipated rather than viewed as a failure of a minimally invasive strategy. In complex dysplasia, the quality and reproducibility of reconstruction outweigh the cosmetic size of the incision, and preservation of muscles should not come at the expense of component malposition. [13]

## Choosing and positioning the femoral stem

Femoral component selection must reconcile the small dysplastic canal with torsional abnormality and the mechanical demands of a potentially shortened femur. Standard cementless stems may fit mildly dysplastic hips

but provide limited independent control of anteversion in extreme deformity. Modular stems offer flexibility in version and offset, while small conical or tapered designs may engage an unusually narrow canal. Each solution involves trade-offs in fixation location, stress transfer and implant-specific complications. Implant choice should follow the anatomy rather than a routine preference transplanted from uncomplicated primary arthroplasty. [14]

Diaphyseal fixation can provide useful rotational control where proximal morphology is distorted, but the surgeon must preserve sufficient intact bone across an osteotomy. The length of the stem, the resection level and the available cortical contact are linked decisions. If the stem bridges a transverse osteotomy without achieving sufficient distal purchase, rotational instability and delayed union may occur. Conversely, an unnecessarily long stem can increase technical difficulty and stress concentration in a small femur. Planning should document the intended fixation zones before bone resection so that shortening does not inadvertently eliminate secure implant support. [15]

The femoral offset influences abductor tension, impingement and leg length, and it should not be corrected by neck lengthening alone. A high-offset option may help restore the lever arm without introducing disproportionate vertical lengthening, but the effect depends on stem geometry and combined version. Trial reductions should assess stability across several movements and inspect mechanical impingement. A hip that appears stable only under considerable traction or at extreme length is not a satisfactory reconstruction. Achieving a balanced construct may require changes to stem version, offset, cup orientation or the amount of shortening. [16]

Intraoperative fractures are a recognized concern when a narrow femur is broached or a stiff stem is inserted. The surgeon should advance preparation incrementally, monitor cortical resistance and maintain a low threshold for direct inspection if an unexpected crack is suspected. Prophylactic cables may be considered in selected fragile geometries but should not replace correct sizing and alignment. A missed fracture threatens both initial fixation and postoperative rehabilitation. Reporting should separate small calcar fissures from major diaphyseal fractures, because their treatment, impact on weight bearing and long-term consequences are different. [17]

## Rationale for femoral shortening

When the cup is restored to the true acetabulum in a high dislocation, the proximal femur may need to travel a large distance to achieve reduction. Forceful reduction risks excessive neural traction, femoral fracture and soft-tissue injury. Subtrochanteric shortening addresses this conflict by removing bone while allowing the hip center to be lowered. The procedure converts an otherwise difficult or unsafe reduction into a more controllable reconstruction, but it introduces a bone-healing site that must resist rotational and bending forces. Its indication should therefore be based on the predicted reduction distance and actual tension, not solely on a classification label. [18]

The amount of resection should integrate the planned center of rotation, pre-existing true and apparent shortening, contracture and desired postoperative soft-tissue tension. A fixed universal threshold is unlikely to be appropriate for all patients. Too little shortening can leave the sciatic nerve under excessive tension; too much can create avoidable residual discrepancy and reduce muscle efficiency. The calculation should be revisited after cup placement and staged releases. Intraoperative assessment remains necessary because static preoperative imaging cannot reliably predict the compliance of contracted tissue. [19]

Shortening also offers an opportunity to correct femoral torsion when the osteotomy is performed at an appropriate level. The proximal and distal fragments can be rotated to improve combined anteversion before stable fixation is achieved. This benefit adds technical complexity because rotational alignment must be maintained throughout stem insertion and healing. Marking the fragments before resection and checking alignment with reliable landmarks can reduce error. Correcting version only by rotating an implant within an unstable canal is less predictable than achieving controlled fixation within a defined bony construct. [20]

The indication for shortening must be balanced against the possibility of using a modestly superior acetabular center or alternative release strategies. A higher center may avoid an osteotomy in some patients but can alter hip mechanics and component loading. Conversely, anatomical cup restoration with shortening may optimize the center while requiring months of osteotomy union. Neither choice is automatically superior. The relevant decision should consider the anticipated benefit of biomechanical restoration alongside surgical morbidity, bone stock, nerve safety and the patient's capacity to follow a protected rehabilitation program. [21]

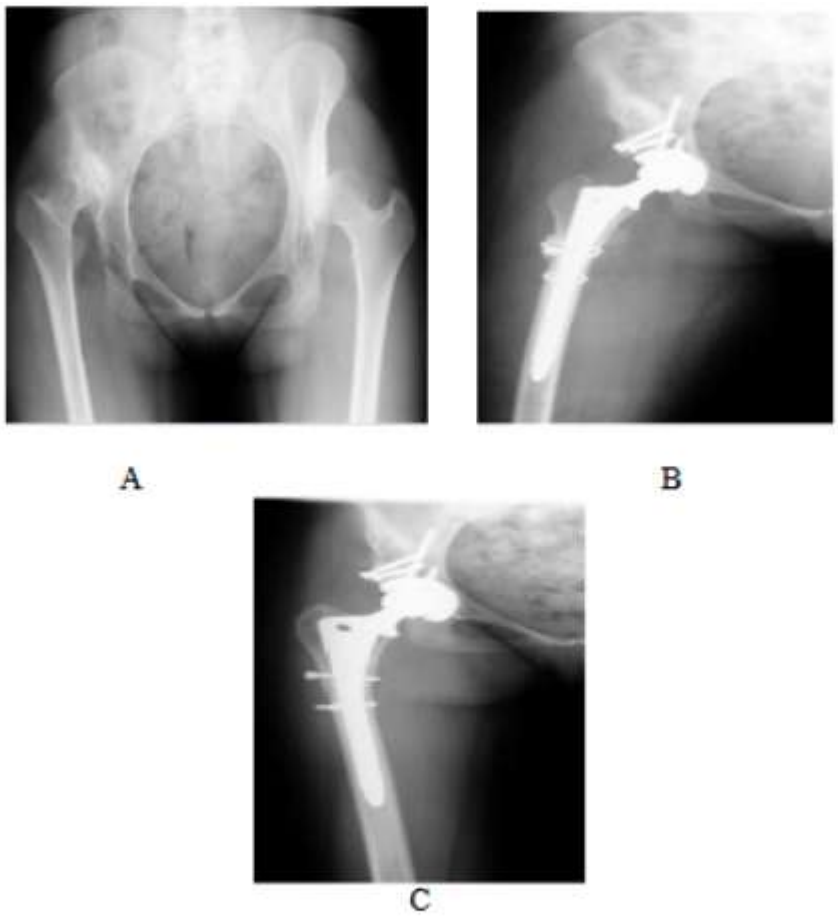


**Figure 1.** Radiographic sequence illustrating reconstruction of a high-riding dysplastic hip with femoral shortening. (A) Preoperative high dislocation with proximal migration of the femur. (B) Postoperative appearance following reduction and femoral reconstruction with a shortening osteotomy. (C) Follow-up imaging demonstrating the reconstructed hip and osteotomy region. The sequence illustrates the need to accommodate excessive reduction distance while restoring femoral alignment.

## Osteotomy geometry and fixation

Transverse subtrochanteric osteotomy is technically straightforward, allows precise adjustment of rotation and can be performed with predictable resection length. Its principal limitation is a smaller contact surface and reliance on stable fixation to resist torsion. Oblique, step-cut and chevron configurations increase contact or inherent rotational resistance but are more demanding to execute accurately in a very narrow femur. Comparative evidence does not justify universal adoption of one cut pattern. Technique should be selected according to canal geometry, implant choice, familiarity and the ability to produce secure compression and rotational stability. [22]

The osteotomy site should be positioned with an understanding of the available distal fixation and the blood supply of the fragments. Excessive stripping of the periosteum or unnecessary fragmentation may reduce healing potential. The stem may provide internal bridging fixation, while cables, plates or cortical strut grafts can supply

supplementary stability when required. The construct should resist torsion during early mobilization, not just appear well aligned on immediate radiographs. The choice of additional fixation is especially relevant when the stem is short, the cut is transverse or the cortices are thin. [23]

Osteotomy healing should be assessed by clinical symptoms and serial radiographs rather than a single early image. Progressive bridging bone, maintained rotation and absence of implant migration are reassuring findings, while persistent pain and radiolucent osteotomy gaps warrant careful evaluation. Nonunion can create micromotion and threaten stem stability, particularly where fixation depends on a short segment of distal cortical engagement. Rehabilitation should be adapted to the stability of the specific construct and the progression of union. A uniform full-weight-bearing schedule may not be suitable for every osteotomy configuration. [24]

Research comparing osteotomy techniques is constrained by small samples and confounding by severity. Surgeons often select more complex cuts or supplemental fixation for difficult anatomy, so crude complication rates cannot establish causation. Studies should report osteotomy level, resection length, rotational correction, stem fixation zones, graft use and the definition of union. These details would allow complications to be linked to a reproducible mechanical explanation. Without them, claims that one geometrical pattern produces faster union or fewer fractures remain uncertain and difficult to translate into individual surgical decisions. [25]

## Nerve protection and controlled lengthening

Sciatic nerve dysfunction is among the most consequential complications of arthroplasty for severe dysplasia. Potential mechanisms include direct instrumentation injury, compression, stretch during reduction, postoperative hematoma and ischemic insult. High dislocation creates particular concern because the femur may be lengthened substantially when the center of rotation is restored. The association between lengthening and neuropathy is complex, and individual tolerance varies. There is no universally safe numerical lengthening threshold that eliminates risk. Prevention rests on atraumatic exposure, staged reduction, informed shortening decisions and careful postoperative neurologic surveillance. [26]

Preoperative examination should establish baseline motor strength and sensory function because prior childhood surgery, lumbar disease or longstanding deformity can create deficits before arthroplasty. Intraoperatively, the surgeon should avoid sustained forceful traction, consider the effect of limb positioning and reassess tension after each reconstructive step. A very tight reduction is a warning sign rather than evidence that the component has achieved ideal stability. Where reduction remains unsafe, additional shortening or a revision of the reconstruction plan may be more prudent than repeated force. [27]

Postoperative neurologic assessment should include ankle dorsiflexion, toe extension, plantar flexion and sensory comparison with the preoperative examination. A new deficit warrants immediate consideration of reversible causes, including compressive hematoma, excessive lengthening, dislocation and component-related compression. Early documentation and targeted imaging are important when the clinical picture suggests a surgically remediable lesion. Some deficits recover with observation and supportive management, but this possibility should not delay assessment for urgent mechanical causes. Patient counseling should distinguish transient neurapraxia from the possibility of persistent weakness. [28]

Interpretation of published nerve-palsy rates is complicated by inconsistent definitions, variable examination schedules and differences in shortening frequency. A study that reports only permanent palsy may appear safer than one documenting transient postoperative deficits. Severe cases also involve longer operative time, greater deformity and more extensive releases, so lengthening alone cannot account for every event. A useful clinical registry would record preoperative neurologic findings, measured change in limb length, osteotomy details, deficit onset and recovery. This would improve risk estimates and help separate preventable technical mechanisms from patient-specific vulnerability. [29]

## Soft-tissue balancing and joint stability

Long-standing dysplastic dislocation remodels the capsule, iliopsoas, short external rotators and abductor musculature. Restoring the center of rotation changes muscle lengths and the position of the femur relative to the pelvis. Soft-tissue releases should be directed at the structures actually preventing reduction rather than performed as a broad routine dissection. Excessive release can undermine stability and weaken function, while inadequate release can force unacceptable lengthening or component malposition. The correct balance is achieved by repeated evaluation of reduction force, range of motion and joint stability as reconstruction proceeds. [30]

Instability after arthroplasty in dysplasia may arise from cup or stem malversion, inadequate offset, impingement, loss of abductor tension or compromise of the posterior soft tissues. The mechanism can be difficult to identify when multiple abnormalities coexist. Trial reductions should assess stability with flexion and internal rotation as well as extension and external rotation, interpreting findings in relation to the chosen surgical approach. Increasing head or neck length may improve tension but worsen leg length or impingement. A mechanism-based correction is preferable to treating every unstable trial by adding vertical length. [31]

Abductor insufficiency is an important source of persistent Trendelenburg gait and dissatisfaction. In high dislocation, muscles may be shortened, atrophic or oriented abnormally, and early postoperative weakness may reflect adaptation rather than failure of the implant. Restoring femoral offset and an effective lever arm helps but does not instantly normalize neuromuscular control. Careful approach selection, tendon preservation and structured rehabilitation are therefore complementary parts of the reconstruction. Functional interpretation should distinguish pain relief from the slower recovery of single-leg stance and walking endurance. [32]

Joint stability must be weighed against the constraints of the small dysplastic acetabulum. Larger heads and dual-mobility constructs may provide additional stability in selected high-risk patients, but their availability depends on shell diameter and implant compatibility. An articulation cannot compensate for gross malposition, inadequate fixation or severe impingement. Moreover, evidence specific to advanced dysplasia is less extensive than evidence from general primary or revision arthroplasty. Implant choice should be individualized and its rationale documented, particularly when abnormal version or abductor compromise is the main concern. [33]

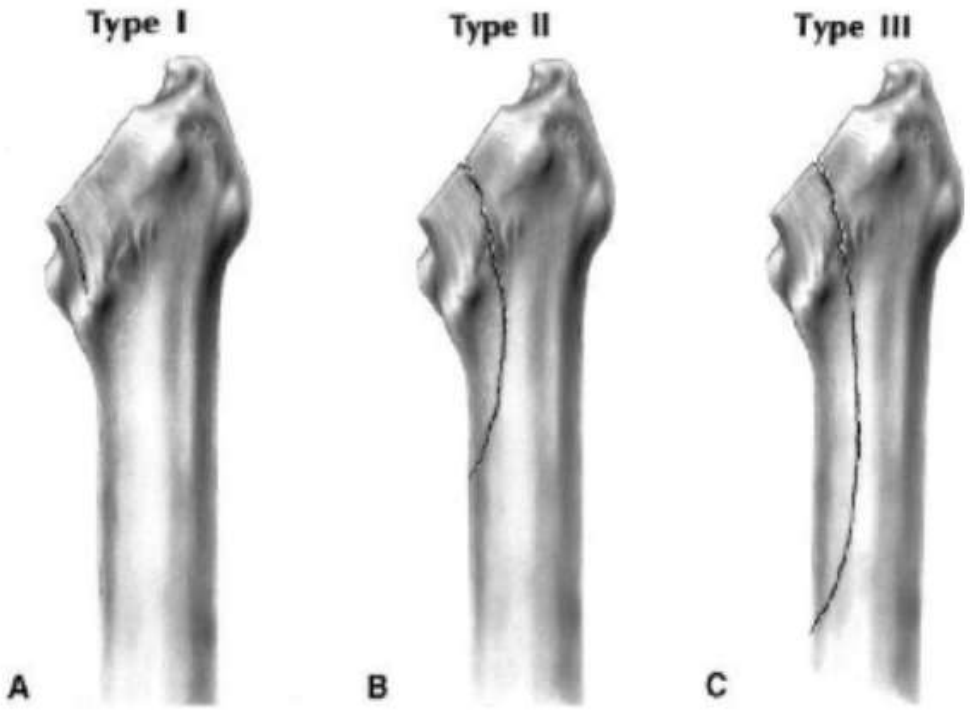


**Figure 2.** Illustrations of three proximal femoral fracture patterns associated with femoral preparation during cementless arthroplasty. Type I is a limited proximal crack; Type II extends farther distally along the proximal metaphysis; and Type III represents an extensive longitudinal fracture. The schematic highlights how fracture extent influences the need for cerclage fixation, stem stability assessment, and postoperative protection.

## Fracture, nonunion and other postoperative complications

Intraoperative femoral fracture is associated with difficult canal preparation, small or sclerotic femora, previous deformity and the use of long stiff implants. Fractures may occur during broaching, stem insertion, reduction or osteotomy fixation. Their clinical importance depends on location, displacement and whether component stability has been lost. Recognizing a fissure immediately permits appropriate cerclage or other fixation, whereas overlooking it may lead to subsidence and delayed recovery. High-quality reports should specify the fracture pattern and subsequent rehabilitation rather than simply recording the event as a binary complication. [34]

Osteotomy nonunion and delayed union deserve separate attention from implant loosening. A stable femoral stem can coexist with an ununited osteotomy, and postoperative pain may have several plausible sources. Serial radiographs should evaluate callus progression, rotational position and distal fixation; CT may be considered when conventional imaging is inconclusive. When union is delayed, mechanical stability, biological health and infection must all be assessed. Revision strategies vary according to the failure mechanism. A biologically sound osteotomy lacking rotational stability requires a different response from a well-fixed construct with compromised healing biology. [35]

Postoperative dislocation is a multifactorial event with particular relevance in dysplasia because of altered anatomy and soft tissues. Early dislocation may expose component malposition, impingement, inadequate abductor tension or an overly aggressive release. Management depends on the timing, recurrence and cause of instability; repeated closed reductions without reviewing the reconstruction can miss a correctable technical problem. Preventive strategies include accurate combined component orientation, appropriate offset, stable soft-tissue repair and selected use of enhanced-stability bearings. The decision must remain sensitive to implant size and available acetabular fixation. [36]

Infection, thrombosis and heterotopic ossification are not unique to dysplasia but contribute substantially to morbidity when recovery is already limited by osteotomy healing or prolonged protected mobilization. Standard perioperative prevention measures should be adapted to the patient's comorbidity burden and procedural complexity. A more difficult operation is not an argument for abandoning established infection or venous thromboembolism protocols. Outcomes research should distinguish systemic postoperative events from deformity-specific structural problems so that the added risks attributable to complex femoral reconstruction can be identified more accurately. [37]

## Rehabilitation and recovery of gait

Rehabilitation after complex dysplastic arthroplasty has two parallel aims: biological protection of the reconstruction and recovery of neuromuscular function. In patients without osteotomy or fracture, mobilization may follow standard arthroplasty principles, whereas a subtrochanteric osteotomy can require restrictions tailored to fixation stability. The early program should emphasize safe transfers, protected loading when prescribed, prevention of falls and restoration of comfortable hip motion. Uniform aggressive strengthening is not appropriate if the femoral construct has not achieved sufficient stability or if substantial soft-tissue release has been performed. [38]

Gait recovery is often slower than pain relief because patients have adapted for years to shortening, pelvic obliquity and reduced abductor efficiency. A previously habitual trunk lean may persist even after radiographic restoration of the hip center. Rehabilitation should include progressive abductor training, balance work, step control and feedback on walking mechanics. It is important to distinguish an expected adaptation period from persistent structural weakness, residual limb-length inequality or an unrecognized nerve deficit. Objective serial examination can prevent vague attribution of every residual limp to slow rehabilitation. [39]

Standing leg-length perception may change during recovery as spinal and pelvic compensations resolve. Patients should be advised that immediate postoperative measurements do not always reflect the final functional discrepancy. An insole or shoe lift may be helpful in selected patients after reassessment, but premature permanent correction may reinforce a transient adaptation. Longitudinal examination of pelvic level, knee position, muscle strength and gait is more informative than a single radiographic figure. The clinical objective is comfortable, stable walking rather than numerical symmetry at any cost. [40]

Outcome studies should incorporate recovery of walking endurance and abductor performance alongside general hip scores. Standard instruments capture pain and everyday function but may be insensitive to compensatory trunk movement or mild neurologic impairment. Recording osteotomy union, rehabilitation restrictions and time to independent walking would help identify the cost of different reconstructive strategies. Such information is particularly relevant when comparing a more anatomical center requiring shortening with a higher center that may allow immediate weight bearing. A comprehensive recovery profile includes the burden and duration of rehabilitation, not only its eventual endpoint. [41]

## Long-term surveillance and research priorities

Long-term follow-up is important because patients with developmental dysplasia often undergo arthroplasty at an age when several decades of implant service may be expected. Surveillance should assess stem subsidence, radiolucent lines, periprosthetic bone changes and late instability in addition to pain and function. An osteotomy that heals successfully can still alter stress transfer along the femur, and a stem that performs well initially may later exhibit fixation problems. Imaging should be interpreted against the immediate postoperative baseline. A high early hip score cannot substitute for evaluation of structural durability. [42]

Systematic reviews of severe dysplasia consistently report substantial clinical improvement while documenting clinically meaningful rates of fractures, dislocations and neurologic events. The studies commonly pool different osteotomy types, approaches, implants and baseline severities. A pooled complication estimate is useful for broad

counseling but should not be presented as the exact risk for an individual patient. The most challenging hips tend to receive complex reconstructions, and many available studies are noncomparative. Differences between techniques therefore remain difficult to isolate from differences in patient selection. [43]

Future research should provide a standardized anatomical description of femoral version, canal dimensions, prior operations, preoperative length discrepancy and intended center of rotation. Operative reports should capture the amount of shortening, osteotomy design, rotational correction, fixation method and actual postoperative length change. Neurologic examination should be prospectively documented and repeated rather than inferred from charted complications. These variables would permit meaningful study of which patients benefit from shortening and whether particular femoral stems or osteotomy geometries reduce adverse events. [44]

The current evidence supports a patient-specific framework rather than a universal operation for every high-riding dysplastic hip. The surgeon must integrate the position and fixation of the acetabular cup with the shape of the femur, the anticipated need for shortening and the condition of the neurovascular and muscular structures. A technically correct component position may still be an unsuccessful overall reconstruction if the hip cannot be reduced safely or the osteotomy cannot heal reliably. The central research task is to make these trade-offs measurable, reproducible and comparable across centers. [45]

## Operative checkpoints and postoperative decision making

An operative checklist for severe dysplasia begins before the incision, with documentation of native femoral version, anticipated stem fit, preoperative neurological status, true shortening and a target hip center. These variables are connected. A planned low acetabular cup may require an osteotomy, which determines the available stem fixation segment and the limits of safe reduction. The implant tray should therefore include compatible alternatives rather than a single preferred design. Complex reconstruction is more predictable when the team knows which element can be changed if the first reduction attempt proves unsafe or unstable. [46]

The trial reduction is a diagnostic moment that integrates the effects of cup position, femoral version, offset and soft-tissue releases. Marked resistance should prompt a search for contracture, inadequate shortening, implant impingement or an improperly positioned component, not merely stronger traction. The surgeon should assess stability without accepting extreme tension as a substitute for balanced anatomy. Repeated forceful manipulation can produce fracture or nerve stretch. A deliberate sequence of inspection, targeted correction and retrial is a safer principle than incremental escalation of force in a mechanically incompatible construct. [47]

Femoral osteotomy must be planned with attention to implant fixation on both sides of the cut. Simply achieving reduction after removal of a bone segment is not enough if the resulting stem can rotate or subside. The available isthmic support, osteotomy pattern and use of supplementary fixation should be assessed together. Recording the resected length and the achieved rotational correction makes subsequent complications easier to understand. A well-positioned radiographic stem does not necessarily guarantee osteotomy stability, and the construct should be tested for rotational security before completion of the procedure. [48]

Staged soft-tissue release is preferable to indiscriminate dissection when the barriers to reduction remain uncertain. Contracted capsular tissue or iliopsoas may require targeted management, while preserved abductor and posterior stabilizing structures can be important for the final joint. Every release changes the stability equation. After additional release, the surgeon should re-evaluate offset, impingement and reduction force rather than proceed under the assumption that the pre-release trial findings remain valid. Avoidable tissue sacrifice may convert a difficult reduction into a hip that reduces easily but lacks lasting stability. [49]

Intraoperative recognition of an impending femoral fracture depends on attention to tactile and visual cues during broaching and stem insertion. Unexpected resistance, a change in instrument trajectory or cortical splitting should trigger immediate inspection. Continuing preparation through a suspected fissure can propagate a minor injury into a major fracture. When fixation is necessary, its adequacy should be evaluated before setting a rehabilitation

protocol. Detailed documentation of the fracture location and treatment permits more rational postoperative restrictions than a generic instruction to protect weight bearing after any difficult surgery. [50]

Neurologic safety should remain part of the final intraoperative assessment. A large length correction accompanied by severe tissue tension may warrant reassessment even when the construct looks satisfactory radiographically. Postoperative examination must be compared with the preoperative baseline and repeated as anesthesia-related effects resolve. New weakness requires prompt investigation of mechanical and compressive causes. Early communication between the surgical team, rehabilitation clinicians and nursing staff improves recognition of a deficit that could otherwise be attributed to pain or temporary postoperative immobility. [1]

Initial rehabilitation orders should reflect the actual reconstruction rather than the procedure name alone. A patient with a well-fixed stem and no osteotomy may be suitable for rapid mobilization, whereas osteotomy fixation, a femoral crack or compromised bone quality may justify a modified loading schedule. The rationale for restrictions should be clear and the criteria for progression based on clinical and radiographic recovery. Overly prolonged restriction can hinder strength and confidence, yet premature unrestricted loading may threaten union. Individualization is essential when the surgical construct departs substantially from routine primary hip replacement. [2]

The interpretation of early postoperative radiographs should include leg length, offset, stem alignment, cup orientation and the position of an osteotomy or fracture fixation. Apparent correction of shortening may be exaggerated by pelvic rotation or altered posture. Comparison with the preoperative plan helps reveal whether an intentionally limited correction was achieved. Serial imaging is particularly important for detecting stem subsidence, loss of rotational control and delayed osteotomy union. Radiographs are not a substitute for examining gait, abductor strength and neurologic recovery, which may progress at different rates. [3]

Persistent limp after surgery deserves a structured evaluation instead of an assumption that the patient needs more exercise. Possible causes include residual abductor weakness, insufficient offset, unresolved pelvic compensation, leg-length perception, neurologic injury and mechanical problems with the reconstruction. Examination of single-leg stance, muscle strength, spinal balance and the knee can refine the diagnosis. Targeted rehabilitation may help when weakness is the main issue, whereas an implant-related cause requires different management. Recognizing these categories prevents delayed diagnosis and improves the accuracy of functional outcome reporting. [4]

At longer follow-up, the surgeon should review implant stability, osteotomy union, late neurologic symptoms, dislocation history and patient activity demands. Severe dysplasia frequently affects younger adults, making long-term structural surveillance relevant even after excellent symptomatic improvement. Studies should report results by femoral morphology and reconstructive technique, not merely by the presence of developmental dysplasia. Such data could identify which combinations of stem geometry, rotational correction and shortening produce durable benefits with an acceptable complication burden. The goal is to convert individual technical experience into evidence that can guide future cases. [5]

## CONCLUSION

Femoral reconstruction in severe dysplasia is most successful when canal geometry, rotation, offset, reduction distance and soft-tissue tension are treated as a single problem. Shortening osteotomy can permit safe reduction at a lower acetabular center, but requires stable fixation and careful assessment of union. Protecting neural structures, recognizing fractures early and individualizing rehabilitation are integral to the operation rather than secondary concerns. Prospective studies with standardized anatomical descriptions and complication reporting are needed to refine surgical choices.

**How to cite this article:** Islam Mohamed Ibrahim Mohamed, Khaled Edris Abdelrahman, El-Sayed El-Etewy Soudy, Ehab Mohamed Shehata (2024). Femoral Deformity, Shortening Osteotomy, and Neurovascular Safety in Complex Dysplastic Hip Reconstruction, Vol. 14, No. 3, 2024,1380-1393

**Source of support:** None.

**Conflict of interest:** Nil.

**Accepted:** 26.03.2024 **Received** 03.03.2024

## REFERENCES

1. Wilkin GP, Ibrahim MM, Smit KM, Beaulé PE. A contemporary definition of hip dysplasia and structural instability: toward a comprehensive classification for acetabular dysplasia. J Arthroplasty. 2017;32(9 suppl):S20-S27. doi:10.1016/j.arth.2017.02.067.
2. Gala, L, Clohisy, J.C, Beaulé, P.E.. Hip dysplasia in the young adult. The Journal of Bone and Joint Surgery, 98(1):63–73. (2016).
3. Schmitz, M.R, Murtha, A.S, Clohisy, J.C, ANTZ Group. Developmental dysplasia of the hip in adolescents and young adults. Journal of the American Academy of Orthopaedic Surgeons, 28(3):91–101. (2020).
4. Decking, R, Brunner, A, Decking, J, Puhl, W, Günther, K.P.. Reliability of the Crowe und Hartofilakidis classifications used in the assessment of the adult dysplastic hip. Skeletal Radiology, 35(5):282–287. (2006).
5. Beltran, L.S, Rosenberg, Z.S, Mayo, J.D, De Avila, F, Bencardino, J.T.. Imaging evaluation of developmental hip dysplasia in the young adult. American Journal of Roentgenology, 200(5):1077–1088. (2013).
6. Jacobsen, S.S, Emmeluth, C, Ovesen, O, Overgaard, S, Søballe, K, Mechlenburg, I.. The interface between periacetabular osteotomy, hip arthroscopy and total hip arthroplasty in the young adult hip. EFORT Open Reviews, 3(7):408–417. (2018).
7. Wang, Y.. Current concepts in developmental dysplasia of the hip and total hip arthroplasty. Arthroplasty, 1(1):1–6. (2019).
8. Onyemaechi, N.O, Anyanwu, E.G, Obikili, E.N, Ekezie, J.. Anatomical basis for surgical approaches to the hip. Annals of Medical and Health Sciences Research, 4(4):487–494. (2014).
9. Thompson, A.L, Cabarcas, B, Ina, J, Ward, G.H, Lachman, N, Sierra, R.J, Hevesi, M.. Anterior hip anatomy for the open hip preservation surgeon. Journal of Cartilage & Joint Preservation, 4(2):100185. (2024).
10. Mac Dermott, K.A.D, Venter, R.G, Bergsteedt, B.J, Pękala, P.A, Henry, B.M, Keet, K.. Anatomical features of the iliocapsularis muscle: a dissection study. Surgical and Radiologic Anatomy, 44(5):599–608. (2022).
11. Pelt, C, Erickson, J.. Skeletally mature acetabular dysplasia. Bone & Joint Research, 5(6):225–231. (2016).
12. Hartofilakidis, G, Stamos, K, Ioannidis, T.T.. Low friction arthroplasty for old untreated congenital dislocation of the hip. The Journal of Bone and Joint Surgery. British Volume, 70-B (2):182–186. (1988).
13. Crowe, J.F, Mani, V.J, Ranawat, C.S.. Total hip replacement in congenital dislocation and dysplasia of the hip. The Journal of Bone and Joint Surgery. American Volume, 61-A (1):15–23. (1979).
14. Hartofilakidis, G, Yiannakopoulos, C.K, Babis, G.C.. Reliability and validity of the Hartofilakidis classification system of congenital hip disease in adults. International Orthopaedics, 33(2):353–358. (2009).
15. Klaue, K, Durnin, C.W, Ganz, R.. The acetabular rim syndrome: a clinical presentation of dysplasia of the hip. The Journal of Bone and Joint Surgery. British Volume, 73-B (3):423–429. (1991).
16. Nunley, R.M, Prather, H, Hunt, D.. Clinical presentation of symptomatic acetabular dysplasia in skeletally mature patients. The Journal of Bone and Joint Surgery. American Volume, 93(Suppl 2):17–21. (2011).
17. Leunig, M, Siebenrock, K.A, Ganz, R.. Rationale of periacetabular osteotomy and background work. Instructional Course Lectures, 50:229–238 / The Journal of Bone and Joint Surgery, 83-A:438–448. (2001).
18. Fredensborg, N.. The CE angle of normal hips. Acta Orthopaedica Scandinavica, 47(4):403–405. (1976).

19. Lynch, T.S, Bedi, A, Kelly, B.T.. The hip-spine relation: sometimes pain isn't in the hip. Current Reviews in Musculoskeletal Medicine, 6(2):139–143. (2013).
20. Anda, S, Svenningsen, S, Dale, L.G, Benum, P.. The acetabular sector angle of the adult hip determined by computed tomography. Acta Radiological: Diagnosis, 27(4):443–447. (1986).
21. Stans, A.A, Pagnano, M.W, Shaughnessy, W.J.. Results of total hip arthroplasty for Crowe type III developmental hip dysplasia. Clinical Orthopaedics and Related Research, 348:149–157. (1998).
22. Bicanic, G, Delimar, D, Harris, W.H.. The high hip center. Clinical Orthopaedics and Related Research, 420:30–35. (2004).
23. Li, H, Wang, L, Dai, K, Zhu, Z.. Autogenous impaction grafting in total hip arthroplasty with developmental dysplasia of the hip. The Journal of Arthroplasty, 28(4):637–643. (2013).
24. Nousiainen, M.T, Maury, A.C, Alhoulei, A, Backstein, D.J, Gross, A.E.. Long-term outcome of shelf grafts in total hip arthroplasty for developmental hip dysplasia. Orthopedics, 32(9):649. (2009).
25. Siegmeth, A, Duncan, C.P, Masri, B.A, Kim, W.Y, Garbuz, D.S.. Modular tantalum augments for acetabular defects in revision hip arthroplasty. Clinical Orthopaedics and Related Research, 467(1):199–205. (2009).
26. Rahbek, O, Kold, S, Zippor, B, Overgaard, S, Søballe, K.. Particle migration and gap healing around trabecular metal implants. International Orthopaedics, 29(6):368–374. (2005).
27. Siebenrock, K.A, Tannast, M, Kim, S, Morgenstern, W, Ganz, R.. Acetabular reconstruction using a roof reinforcement ring with hook for total hip arthroplasty in developmental dysplasia of the hip-osteoarthritis: minimum 10-year follow-up results. The Journal of Arthroplasty, 20(4):492–498. (2005).
28. Karachalios, T.H, Roidis, K.N, Hartofilakidis, G.. Acetabular reconstruction in patients with low and high dislocation: 20- to 32-year survival of an impaction grafting technique (named Cotyloplasty). The Bone & Joint Journal, 95-B (7):887–892. (2013).
29. Dorr, L.D, Tawakkol, S, Moorthy, M, Wan, Z.. Medial protrusio technique for placement of a porous-coated, hemispherical acetabular component without cement in a total hip arthroplasty in patients who have acetabular dysplasia. The Journal of Bone and Joint Surgery. American Volume, 81(1):83–92. (1999).
30. Cameron, H.U, Botsford, D.J, Park, Y.. Influence in congenital hip dysplasia: J Arthroplasty of the Crowe rating on the outcome of total hip arthroplasty. The Journal of Arthroplasty, 11(5):582–587. (1996).
31. Oldenburg, M, Müller, R.T.. The frequency, prognosis and significance of nerve injuries in total hip arthroplasty. International Orthopaedics, 21(1):1–3. (1997).
32. Farrell, C.M, Springer, B.D, Haidukewych, G.J, Morrey, B.F.. Motor nerve palsy following primary total hip arthroplasty. The Journal of Bone and Joint Surgery. American Volume, 87(12):2619–2625. (2005).
33. Eggli, S, Hankemayer, S, Müller, M.E.. Nerve palsy after leg lengthening in total replacement arthroplasty for developmental dysplasia of the hip. The Journal of Bone and Joint Surgery. British Volume, 81-B (5):843–845. (1999).
34. Furnes, O, Lie, S.A, Espehaug, B, Vollset, S.E.. Hip disease and the prognosis of total hip replacements: a review of 53,698 primary total hip replacements reported to the Norwegian Arthroplasty Register 1987-99. The Journal of Bone and Joint Surgery. British Volume, 83-B (4):579–586. (2001).
35. Berend, K.R, Lombardi, A.V, Mallory, T.H, Adams, J.B.. Cerclage wires or cables for the management of intraoperative fracture associated with a cementless, tapered femoral prosthesis: results at 2 to 16 years. The Journal of Arthroplasty, 19(7 Suppl 2):17–21. (2004).
36. Morgenstern, R, Denova, T.A, Khan, I, Carroll, K.M, Su, E.P.. Total hip arthroplasty utilizing an uncemented, flat, tapered stem with a reduced distal profile. Arthroplasty Today, 5(4):510–515. (2019).
37. Krych, A.J, Howard, J.L, Trousdale, R.T, Cabanela, M.E.. Total hip arthroplasty with shortening subtrochanteric osteotomy in Crowe type-IV developmental dysplasia. The Journal of Bone and Joint Surgery. American Volume, 91(9):2213–2221. (2009).
38. Sochart, D.H, Porter, M.L.. The long-term results of Charnley low-friction arthroplasty in young patients who have congenital dislocation, degenerative osteoarthrosis, or rheumatoid arthritis. The Journal of Bone and Joint Surgery. American Volume, 79(11):1599–1617. (1997).

39. Brooker, A.F, Bowerman, J.W, Robinson, R.A, Riley, L.H.. Ectopic ossification following total hip replacement: incidence and a method of classification. The Journal of Bone and Joint Surgery. American Volume, 55(8):1629–1632. (1973).

40. Mortazavi, S.M, Restrepo, C, Kim, P.J, Parvizi, J.. Cementless femoral reconstruction in patients with proximal femoral deformity. The Journal of Arthroplasty, 26(3):354–359. (2011).

41. Pierchon, F., Migaud, H., Duquennoy, A. and Fontaine, C. (1993) 'Évaluation radiologique du centre de rotation de la hanche' [Radiologic evaluation of the rotation center of the hip], Revue de Chirurgie Orthopédique et Réparatrice de l'Appareil Moteur, 79(4), pp. 281–284.

42. Ranawat, C.S, Dorr, L.D, Inglis, A.E.. Total hip arthroplasty in protrusio acetabuli of rheumatoid arthritis. The Journal of Bone and Joint Surgery. American Volume, 62-A (7):1059–1065. (1980).

43. Walker, R.P, Gee, M, Wong, F, Shah, Z.. Functional outcomes of total hip arthroplasty in patients aged 30 years or less: a systematic review and meta-analysis. Hip International, 26(5):423–431. (2016).

44. Salman, L.A, et al.. The outcomes of total hip arthroplasty in developmental dysplasia of the hip: a systematic review and meta-analysis. Arthroplasty Today, 22:101168. (2023).

45. Parilla FW, Anthony CA, Bartosiak KA, Pashos GE, Thapa S, Clohisy JC. Ten year outcomes of contemporary total hip arthroplasty in adolescent and young adult patients are favorable. J Arthroplasty. 2024;39(3):754-759. doi:10.1016/j.arth.2023.09.032.

46. Glassman, A.H, Engh, C.A, Bobyn, J.D.. A technique of extensile exposure for total hip arthroplasty. The Journal of Arthroplasty, 2(1):11–21. (1987).

47. Kerboull, L.. Selecting the surgical approach for revision total hip arthroplasty. Orthopaedics & Traumatology: Surgery & Research, 101(1):S171–S178. (2015).

48. Wu C, Shu G, Xie X, Yuan X, Chen S. Meta-analysis of the efficacy of the anatomical center and high hip center techniques in the treatment of adult developmental dysplasia of the hip. Biomed Res Int. 2022;2022:7256664. doi:10.1155/2022/7256664.

49. Qian H, Wang X, Wang P, Zhang G, Dang X, Wang K, et al. Total hip arthroplasty in patients with Crowe III/IV developmental dysplasia of the hip: acetabular morphology and reconstruction techniques. Orthop Surg. 2023;15(6):1468-1476. doi:10.1111/os.13733.

50. Esmaeili S, Ghaseminejad-Raeini A, Ghane G, et al. Total hip arthroplasty in patients who have Crowe type IV developmental dysplasia of the hip: a systematic review. J Arthroplasty. 2024;39(10):2645-2660.e19. doi:10.1016/j.arth.2024.05.031.